

Histological study of the retina of *Gallus domesticus*

Dr. Rehana Parveen

Lecturer, Department of Zoology, Government Meera Girl's College (MLSU), Udaipur

ARTICLE DETAILS

Article History

Received: 25 December 2016

Accepted: 14 January 2017

Published Online: 19 January 2017

Keywords

Gallus domesticus, rod, layer,
nerve fiber

ABSTRACT

The histological organization of retina of *Gallus domesticus* shows presence of numerous cones as compared to rods. The outer plexiform layer (OPL) is thin than inner plexiform layering (IPL). The INL is multi-layered while ONL is thin. The layer of nerve fiber (NF) is thick.

1. Introduction

There are hardly any doubts about the highly developed vision in birds. Walls (1942) had suggested that animals that travel at great speed would need very good vision so as enables them for efficient perception on in movement. The retina, first senses the light, integrates the information, and then passes this on to the brain in the form of nerve impulses. The retina of bird has been said to represent the ultimate in the retinal organization (Werblin and Dowling, 1969; Cobb 1964) investigated the histological structure of optic lobe *Pumphocelusdi miniatus*. The Literatures lacking accounts on the histological structure of retina of *Gallus domesticus*. Therefore is must be necessary to know the histological structure of the retina.

2. Material and methods

The health *Gallus domesticus* of local poultry form were used for the present study. The adult animal of both sexes of age 2-3 months were used for the study. The retina was quickly removed and small pieces were fixed in bouin's fixatives for 24 hrs. After thorough washing in running water, the retina was processed for dehydration and paraffin blocks were prepared. The section of 3-4 mu thickness were cut and processed for haemato-xyline and eosin staining (Harrison, 1962) to reveal histological detail.

3. Result and discussion

The different layers of retina of *Gallus domesticus* are distinguished as pigmented epithelium (PE) , layers of rods and cones (LRC) , outer limiting member(OLM) ,Outer nuclear layer (ONL)Inner nuclei layer (INL), inner plexiform layer (IPL), ganglion cell layer (GC), layers of nerve fibers (LNF),Inner limiting membrane (ILM), PE- is the outermost layer, filled with black pigment, LRC – This layer composed of both types of photoreceptors. The cones are numerous and rods are few, OPL – is the first synaptic layer having the synaptic contact between the photoreceptors and the horizontal cells and OPL is thin. INL – These cells composed of various types of neurons. It is very thick and multi layered divided into three zones. Upper zone having horizontal cells, middle zone composed of bipolar cells and amacrine cells present in the lowermost zone of INL, IPL – This is the second synaptic layer and is thick as compared to OPL. This IPL is composed of the synaptic contact between axons of bipolar and amacrine cells and dendrites of third order of neurons, I.e. ganglion cell, GC –The ganglion cells are very well developed and arranged in two rows, LNF –The axons of GC arranged into nerve fiber bundle, to make the LNF of retina. As number of bipolar cells and amacrine cells are increased in the duplex retina, the IPL becomes thick accordingly, In the IPL three bands show distinct levels of synaptic contacts of bipolar and various types of the amacrine cells with the ganglion cells, LNF is thick in duplex retina of *Gallus domesticus*.

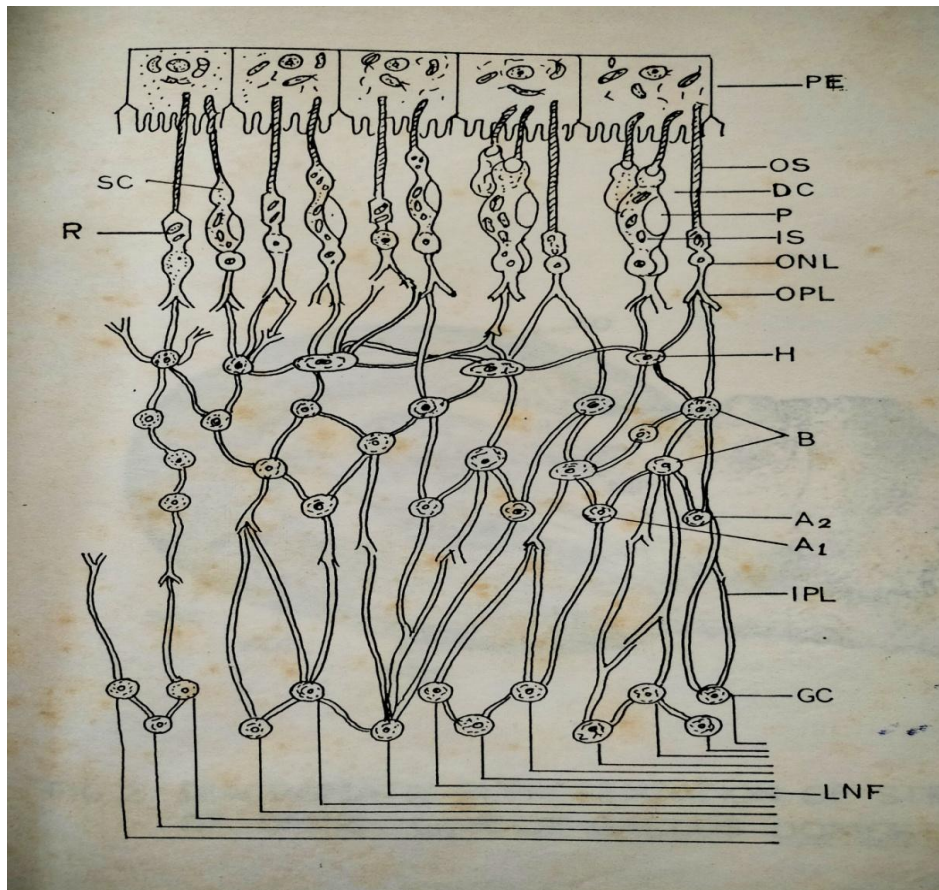


Figure 1- Diagrammatic representation of structure of retina of *Gallus domesticus*




Figure 2- High power photomicrography of the *Gallus domesticus* retina: (1) observed various layers in the retina – layers of rods and cones (LRC), Outer nuclear layer (ONL), outer plexiform layer (OPL), inner nuclear layer (INL); (2). Outer segments (OS), Inner

segment (IS), Paraboloid body in the IS (P), Double cone (DC), Single cone (SC), nuclei in the ONL (N), horizontal (H), Bipolar (B) and Amacrine cells (A); (3). Inner plexiform layer (IPL), ganglion cells (GC) and layer of nerve fibers (LNF); (4). The axon of amacrine cells entering inner plexiform layer (arrow). Note the horizontal stratification in the IPL (S-arrows), Also note the presence of synaptic contacts between the dendrites of the ganglion cells and the axons of the cells (GC) and the layer of nerve fibers (LNF) and clearly visible.

Reference –

1. Cobb, S. (1964). A comparison of the size of an auditory nucleus (n. mesencephalicus lateralis, pars dorsalis) with the size of the optic lobe in twenty seven species of birds. *Journal of Comparative Neurology*. 122; PP- 271-299.
2. Walls , G.C. (1942). The vertebrates eye and its adaptive radiation. *Carnbrook institute of science bulletin number*. 19.
3. Werblin, F.S. and Dowling,J.E. (1969). Organization of the retina of mud guppy (*Necturus maculosa*). II. Intra cellular recording. *Journal of Neurophysiology*. Volume 32,pp-339-355.
4. Harrison, R.J. (1962). The structure of ovary- mammals. In : *The Ovary*, (S.Zukerman Ed. Academic press, New York, Volume I, chapter II, C,P.143.